

SURGERY OF GLAUCOMA IN MODERN CORNEAL GRAFT PROCEDURES

Prof. Jorge L. Alió MD, PhD

VISSUM

Instituto Oftalmológico de Alicante

Universidad Miguel Hernández

Alicante (Spain)



INTRODUCTION (I)

- Glaucoma is a major cause of vision loss in corneal transplant cases.
- A major risk factor for graft failure (second leading cause of corneal graft failure).
- Glaucoma may present before corneal transplant surgery or increased intraocular pressure may develop after keratoplasty.
- The two major risk factors for developing glaucoma after any type of corneal graft :
 - The anti-rejection steroid treatment.
 - Pre-existing glaucoma.

INTRODUCTION (II)

- Chronic or acute IOP elevation can potentially compromise the graft endothelial function and can lead to endothelial cell loss (10–33%).
- Mechanisms of IOP elevation with keratoplasty:
 - The collapse of the iridocorneal angle.
 - Steroid induced hypertension.
 - Postoperative inflammation.
 - Iatrogenic injury of the angle during surgery.

Foulks GN: Glaucoma associated with penetrating keratoplasty. Ophthalmology 94:871–4, 1987

Ayyala RS. Penetrating keratoplasty and glaucoma. Surv Ophthalmol. 2000; 45:91–105.

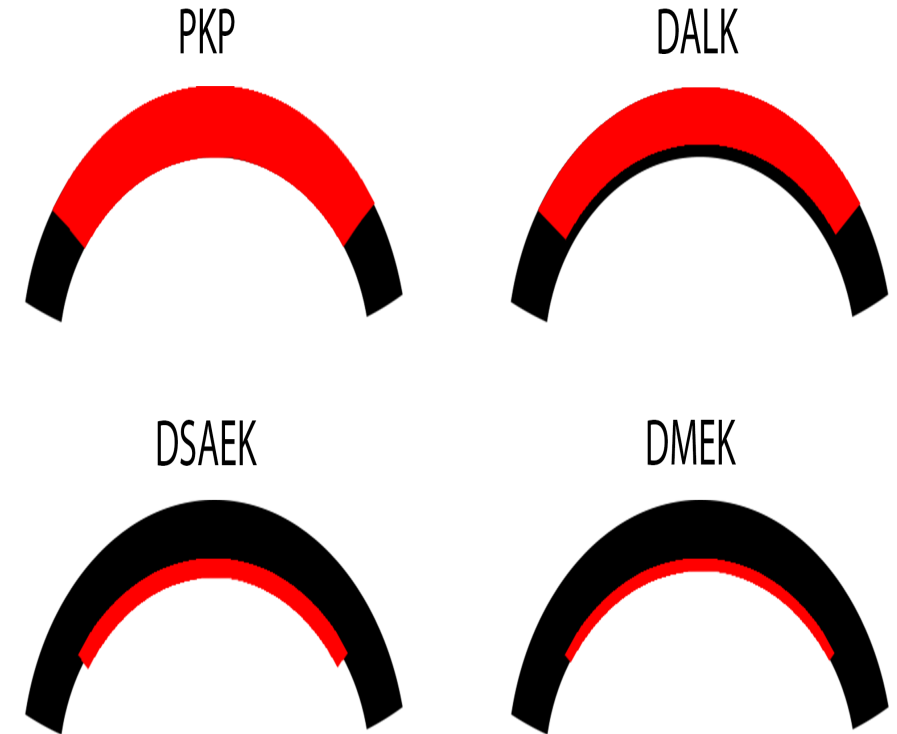
INTRODUCTION (III)

- Early diagnosis and management of glaucoma in corneal transplant surgery can lead to fewer complications and improves outcomes.

- One major advantage of modern selective lamellar keratoplasty is the reduced risk of glaucoma compared to PKP:
 - Less destructive surgical nature of the lamellar procedures.
 - The reduced use of postoperative steroid treatment.

MODERN CORNEAL GRAFT SUMMARY

- PENETRATING KERATOPLASTY AND GLAUCOMA.
- LAMELLAR PROCEDURES AND GLAUCOMA.
 - DALK.
 - DSAEK.
 - DMEK.
- GLAUCOMA SURGERY PROCEDURES IN CORNEAL GRAFTED EYES.

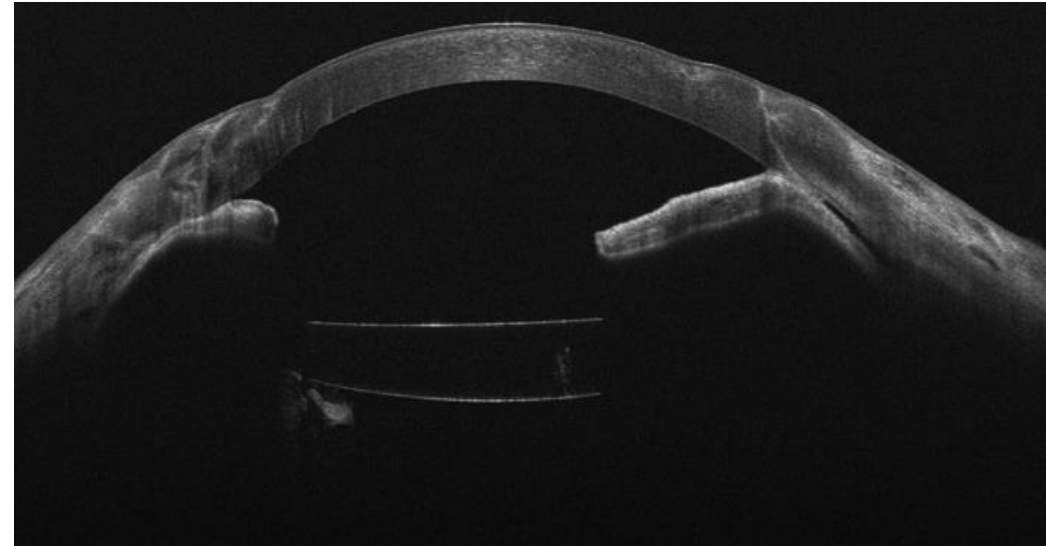


○ **PKP AND GLAUCOMA**

Glaucoma following PKP (10-53%)

Preoperative risk factors

- Young patient age.
- Pseudophakia.
- Aphakia.
- Perforated corneal ulcer.
- Peripheral anterior synechiae.
- Floppy iris.
- Trauma.
- Preexisting glaucoma.
- Previous anterior segment surgery.

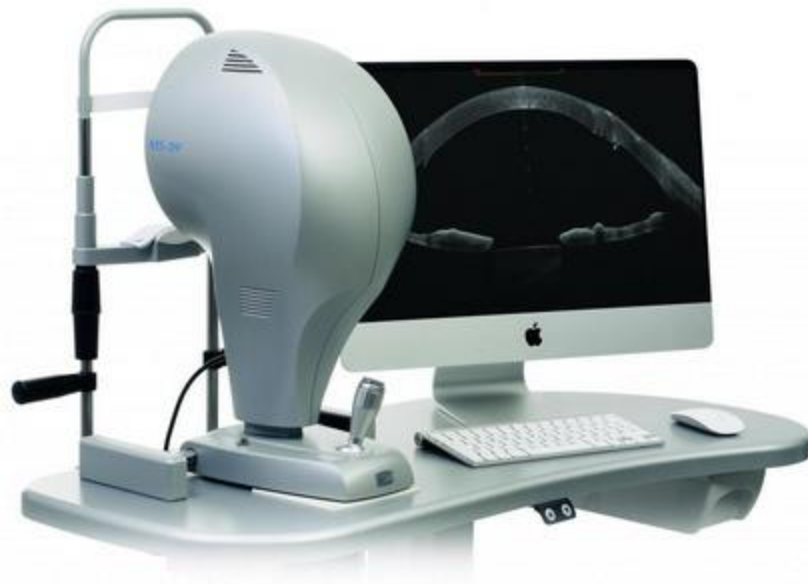
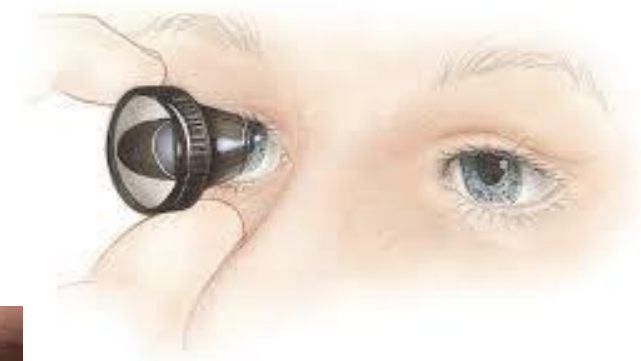

Huber KK, Maier AK, Klamann MK, et al. Glaucoma in penetrating keratoplasty: risk factors, management and outcome. Graefes Arch Clin Exp Ophthalmol. 2013; 251:105–116.

Al-Mohameed, M., Al-Shahwan, S., Al-Torbak, A., Wagoner, M.D. Escalation of glaucoma therapy after penetrating keratoplasty. Ophthalmology. 2007; 114, 2281–2286.

Preoperative careful evaluation of the anterior segment is important by :

- Slit lamp.
- Gonioscopy.
- AS-OCT.



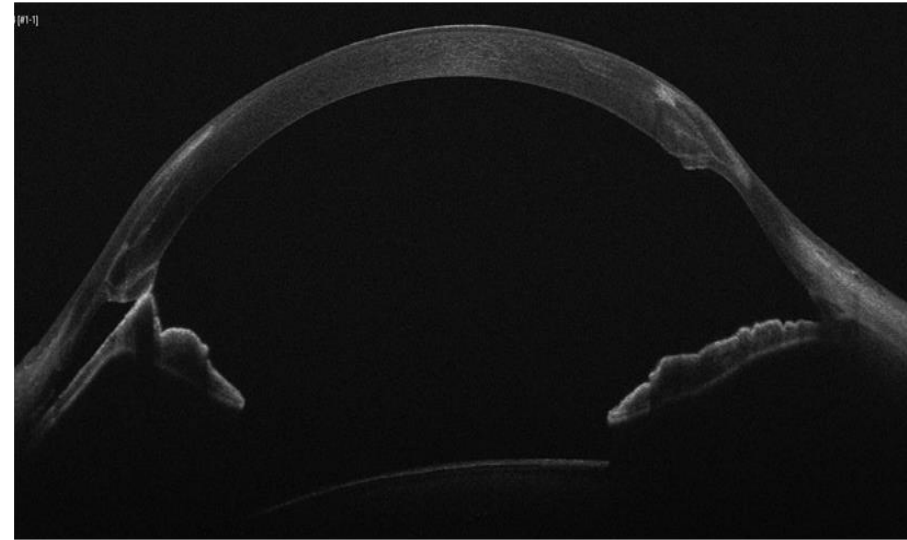
Operative risk factors

- Changes in iridocorneal angle with distortion and collapse of trabecular meshwork which increases aqueous outflow resistance **DUE TO:**
 - Tight sutures.
 - Undersized graft.
 - Larger trephine size.
 - Iatrogenic injury to iridicorneal angle.
- Viscoelastic or vitreous prolapse into the angle.

Ideal to make the donor size 0.5 mm larger or better femtosecond assisted.

Postoperative risk factors

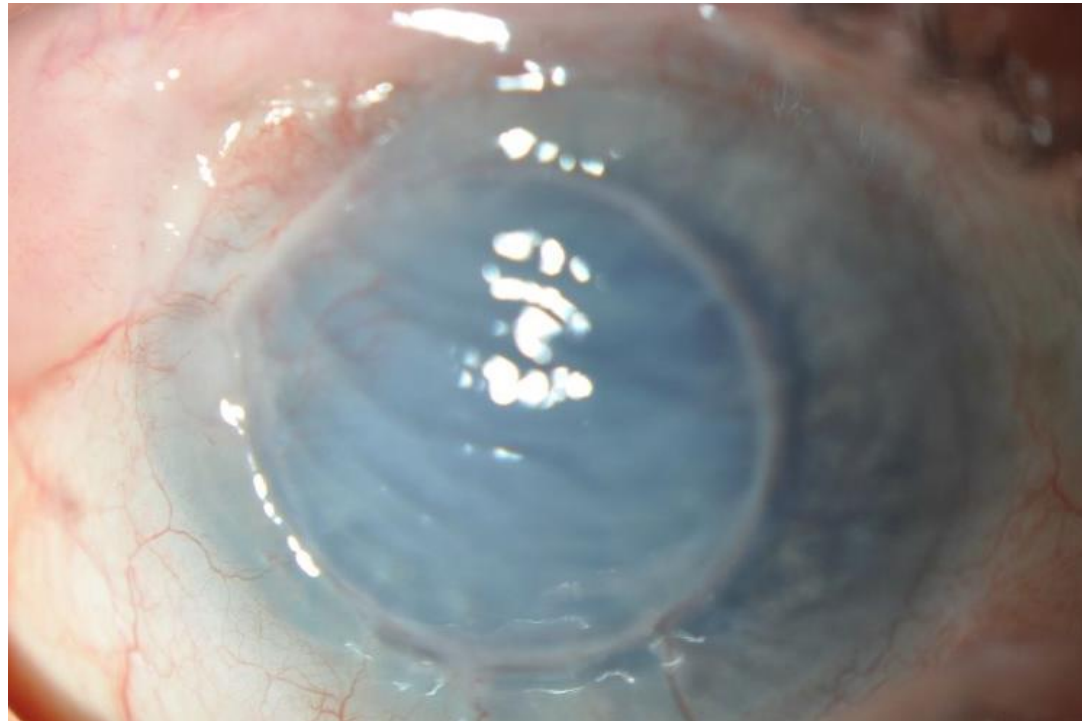
- Postoperative inflammation.
- Peripheral synechiae.
- Steroid induced glaucoma.



IF happened: replacing the steroids by other anti rejection drugs such as cyclosporine, IOP mostly returns to normal values within 1 to 4 weeks after the steroid treatment has been discontinued.

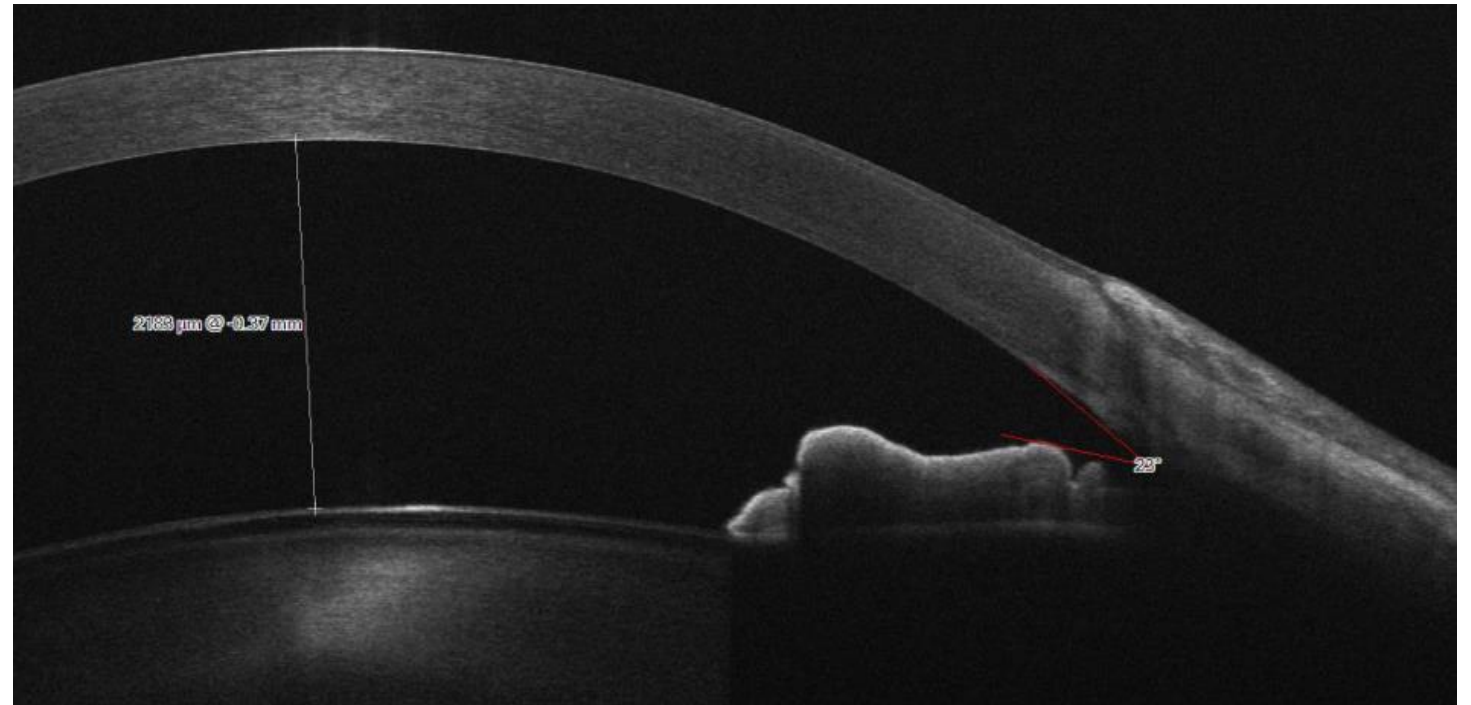
Perry et al. found an average IOP reduction of 8.7 mm Hg after switching patients from topical corticosteroid to cyclosporine A 0.5%.

- It was reported that graft survival for 10 years postoperatively was 58% in patients with glaucoma versus 80% in patients without glaucoma.

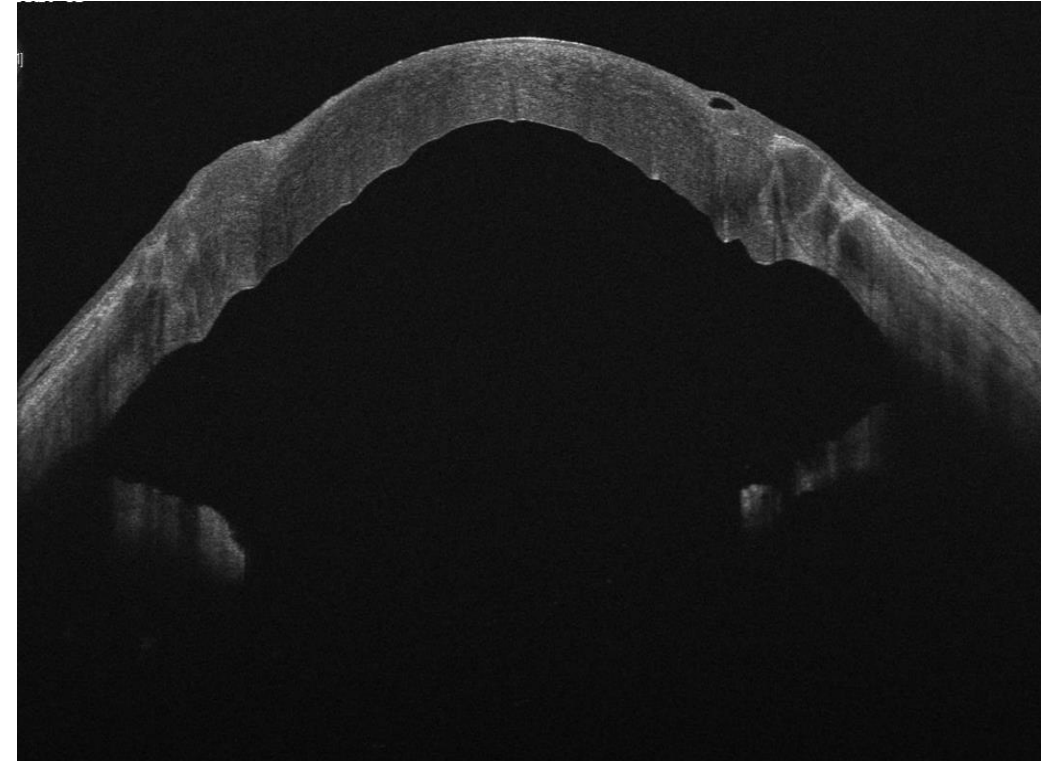


FN:195138

- High resolution AS-OCT : has a great role in these cases for better decision making as it shows:
 - AC angle abnormalities.
 - AC depth.
 - AC anatomy.
 - Iris attachment.



- 64 years old male, who underwent PKP for corneal decompensation following cataract surgery.
- IOP was elevated following PKP.
- By AS-OCT, the angle was open and the patient was adequately managed and IOP was controlled with only topical anti glaucoma therapy.



FN:768124

- The most important step is early diagnosis which is not so simple due to ***decreased reliability of IOP measurements after PKP*** due to :
 - Corneal irregularity.
 - Presence of graft edema.
 - If there is absence of graft epithelium in early postoperative period.



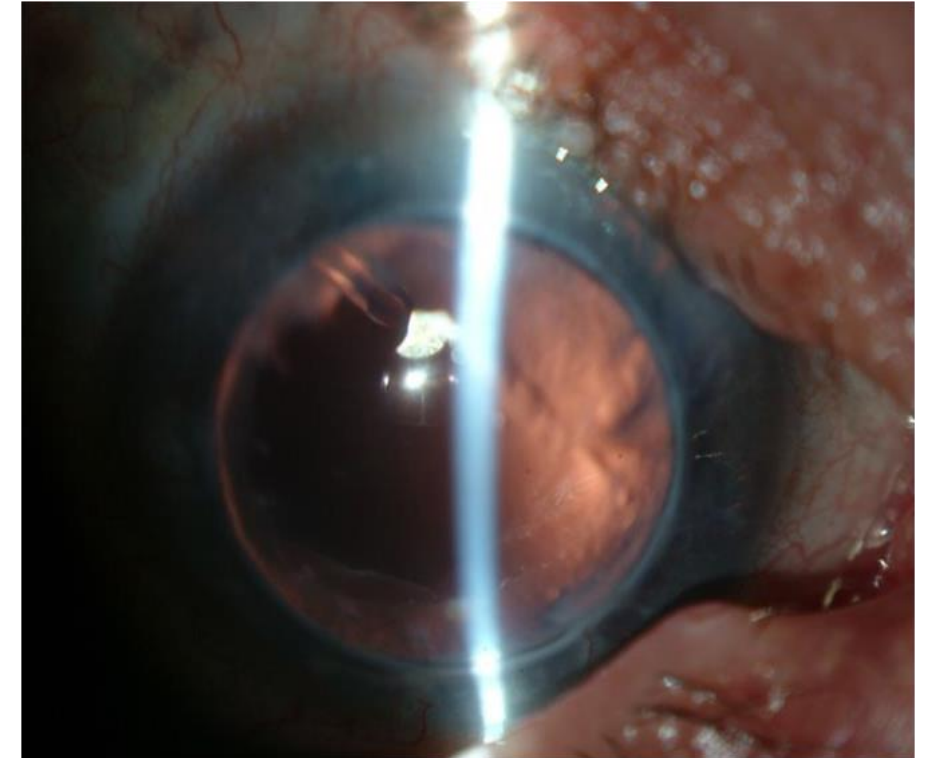
○ Management

- Medical treatment immediately and reduce steroid dose.
- The largest reduction of IOP is achieved with prostaglandins, followed by beta-blockers, alpha-adrenergic agonists and topical carbonic anhydrase inhibitors or steroid replacement could be better.
- Preservative free antiglaucoma drops especially with ocular surface problems.
- Surgical options:
 - . Poor glaucoma control with topical medications.
 - . Complications from topical therapy.

- Prior glaucoma surgery seems to increase the failure rates.
- *Stewart et al.* reported that the 3 year survival rates for PKP grafts at 3 years:
 - 72% in eyes with glaucoma.
 - 63% in eyes with previous glaucoma surgery.
 - 86% in eyes without glaucoma.
- The long term survival of PKP grafts in eyes with GFD is generally not good, the reported 1 year incidence of graft failure ranging from 8% to 51%.

Ahmed valve for uncontrolled glaucoma after PKP

- We report a case of 60 years old female that required a PKP for an aphakic bullous keratopathy. She was with antiglaucoma therapy already (3 molecules)
- She eventually required the subsequent implant of Ahmed's valve in order to control the high values of IOP.
- 3 years later the graft failed ...

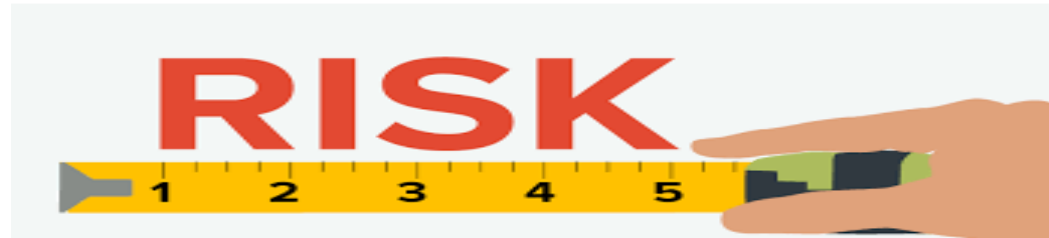

FN:195138

- The reported PKP graft survival rate in eyes with different types of GFD is 58.5% to 92 % at 1 year after PKP, and falls to 25.8% to 70% at 2 to 3 years after PKP.

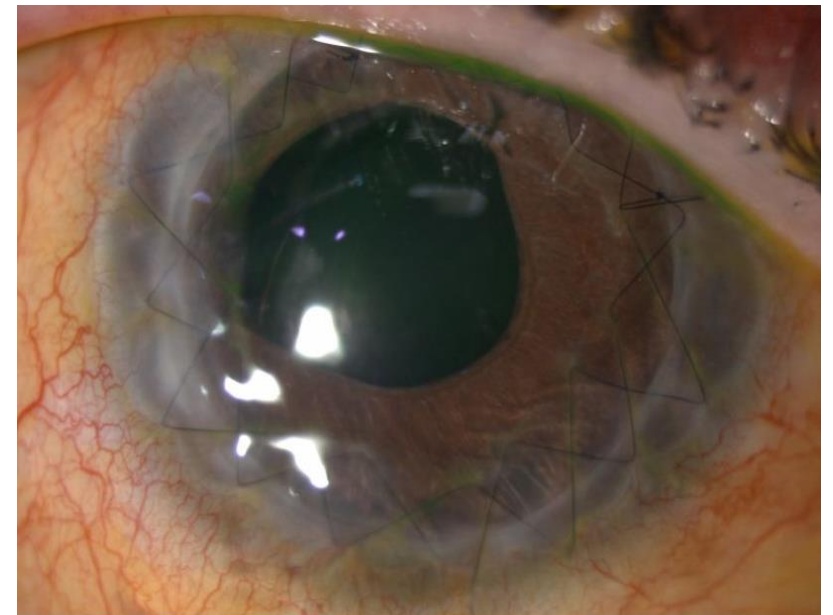
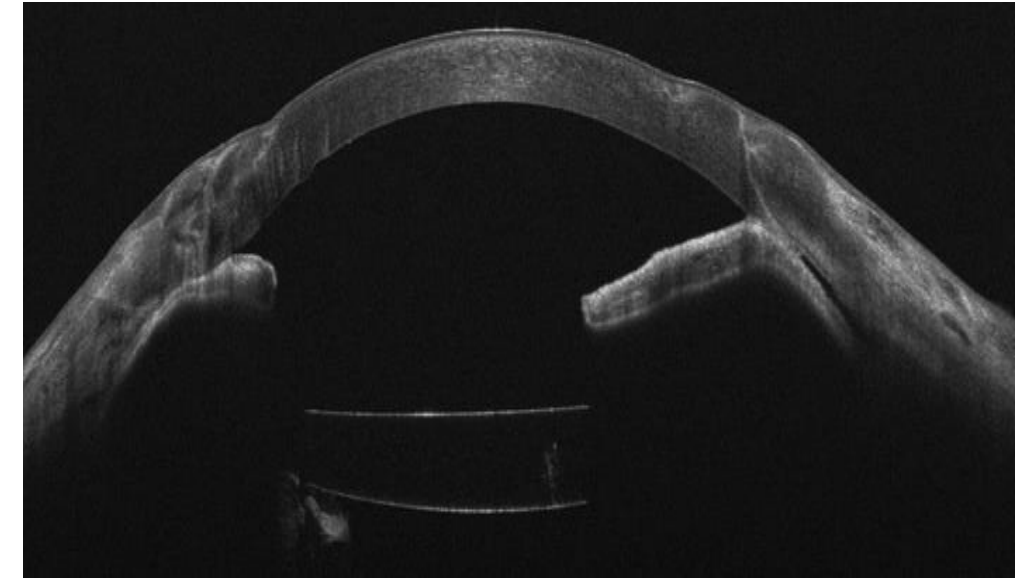
- In a study by *Hollander et al*, the reported PKP graft survival rates after single type of GFD (Ahmed valve):
 - 57.7% at 1 year.
 - 42.9% at 2 years.
 - 40.9% at 3 years.

- Tube trimming of GDD may be needed at time of PKP to avoid touch with graft endothelium.
- Escalation of glaucoma therapy may be needed after PKP. As IOP control is very important for graft survival.



[Iverson SM](#), [Spierer O](#), [Papachristou GC](#), [Feuer WJ](#), [Shi W](#), [Greenfield DS](#), [O'Brien TP](#). Comparison of graft survival following penetrating keratoplasty and Descemet's stripping endothelial keratoplasty in eyes with a glaucoma drainage device. [Int Ophthalmol](#). 2018 Feb;38(1):223-231.

- A 48 years old female with PKP performed for corneal decompensation from phakic IOL.
- Cataract surgery and phakic IOL explantation was performed later.
- After that, IOP was elevated and Express valve was implanted for medically uncontrolled IOP elevation.
- 7 years later, IOP was elevated again.
- By AS-OCT , the tip of the valve was closed by fibrosis and there is iridocorneal adhesion.
- It was managed by removal of fibrous tissue and dissection of the adhesion.



CASE REPORT (FN: 614591)



Glaucoma after lamellar corneal surgery

- *DMEK.*
- *DSAEK.*
- *DALK.*

DMEK



DSAEK



DALK



Glaucoma after DMEK

- Glaucoma is the most serious complication that may occur after DMEK.
- It was defined by *Naveiras et al.* as an IOP >24 mmHg or an elevation of >10 mmHg above the preoperative levels.
- It was reported that 12- month incidence of IOP elevation after DMEK ranging from 6.5% to 11.1%.

○ **Pathogenesis**

- **Early**

. Air bubble-induced mechanisms.

- **Late**

. Persistent inflammation.

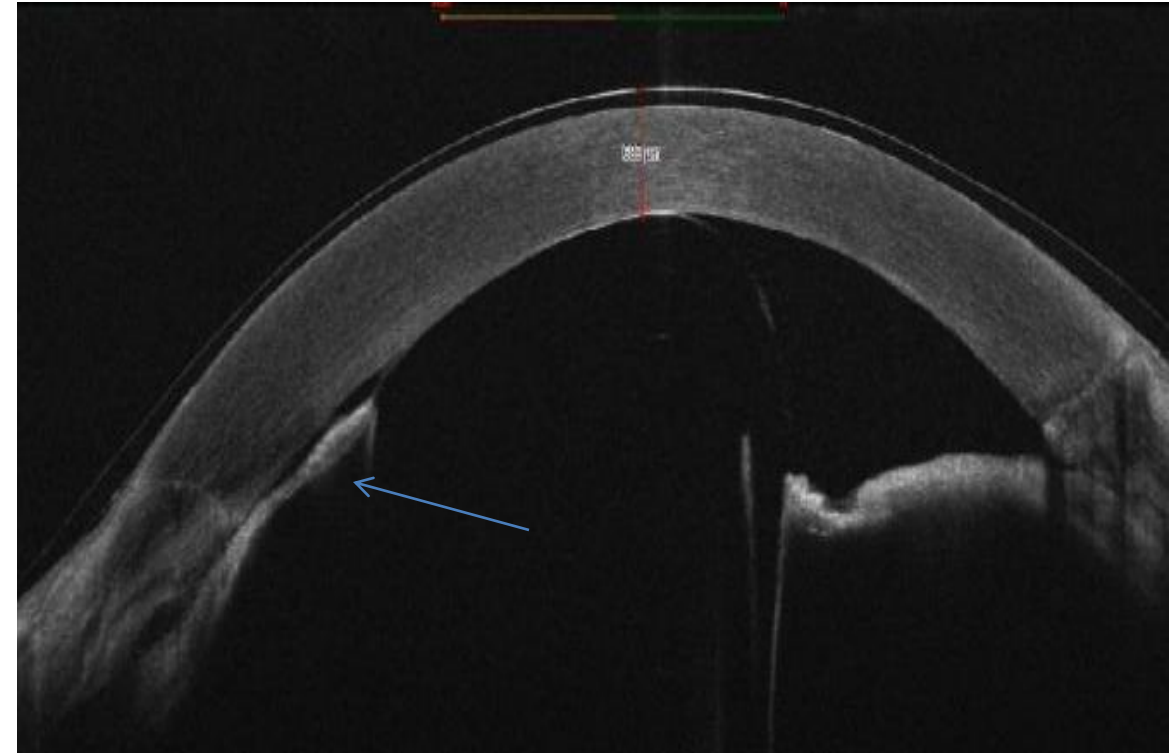
. Peripheral anterior synechiae.

. Descemet membrane adhesions.

. **Steroid response.**

○ Reported de novo glaucoma rates after DMEK range from 2.8 to 6.5%.

○ *Naveiras M, Dirisamer M, Parker J, et al. Causes of glaucoma after Descemet membrane endothelial keratoplasty. Am J Ophthalmol. 2012; 153:958–966.*



FN: 80411

○ Management

Prophylactic measures are always preferable before DMEK like :

- . Inferior peripheral laser iridotomy.
- . Air bubble with a volume less than 80% of anterior chamber volume is recommended.
- . Weaker steroids such as fluorometholone 0.1% can be used as low rejection risk with DMEK.

Naveiras M, Dirisamer M, Parker J, et al. Causes of glaucoma after Descemet membrane endothelial keratoplasty. Am J Ophthalmol. 2012; 153:958–966.

Gorovoy MS. DMEK Complications. Cornea. 2014; 33(1):101–4.

- **Medical ttt**

- For pupillary block by air bubble**

- Pupillary dilatation.
- Oral acetazolamide.
- Making the patient to lie in supine position in 1 to 2 hours.
- If IOP continues to remain high, careful release of air from anterior chamber may be required.

- **For glaucoma due to PAS**

- Glaucoma implant with caution not to affect the graft survival.
- *Naveiras M, Dirisamer M, Parker J, et al. Causes of glaucoma after Descemet membrane endothelial keratoplasty. Am J Ophthalmol.*

Glaucoma after DSAEK

- The frequency of glaucoma after DSAEK varied between 0-15 %
From the results of 23 studies performed with follow up period (3-18) months.

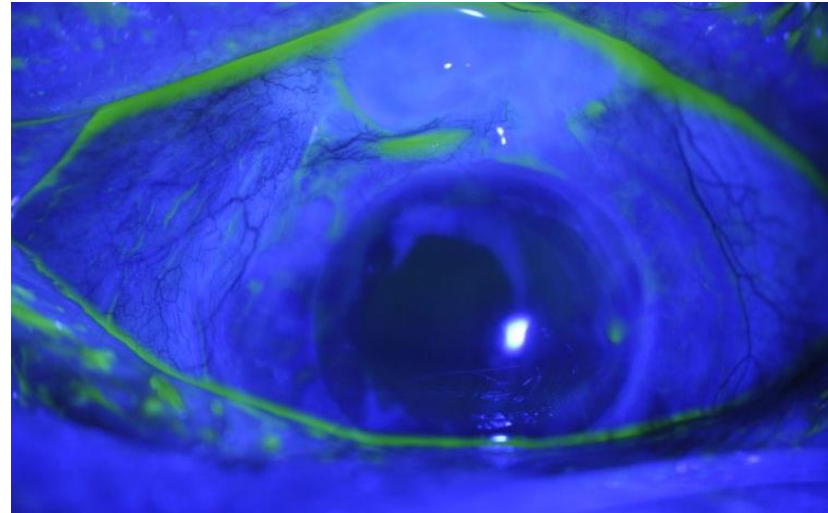
- ***Pathogenesis*** as mentioned with DMEK.
- The commonest cause is the ***steroid use*** with a reported incidence 18.6%.

Maier, A.K., Klamann, M.K., Torun, N., Gonnermann, J., Schroeter, J., Jousen, A.M., Rieck, P. Intraocular pressure elevation and post-

DSEK glaucoma after Descemet's stripping endothelial keratoplasty. Graefes Arch. Clin. Exp. Ophthalmol.2013; 251, 1191–1198.

○ Management

- As mentioned before for DMEK.
- The preferred surgical procedure for glaucoma after DSAEK is not clearly defined.
- Trabeculectomy is the most frequent filtering procedure reported.



FN: 767249

Glaucoma after DALK

- Less risk of glaucoma as there is no distortion of the angle as in PKP, as well as there is no viscoelastic use.
- The incidence of glaucoma after DALK procedure has been reported, varying from 4.48% to 17 % in a 5 years follow up study.
- The most common cause of IOP elevation after DALK is the topical steroid use.

Huang OS, Mehta JS, Htoon HM, Tan DT, Wong TT. Incidence and Risk Factors of Elevated Intraocular Pressure Following Deep Anterior Lamellar Keratoplasty. Am J Ophthalmol. 2016; 170:153–60.

○ Management

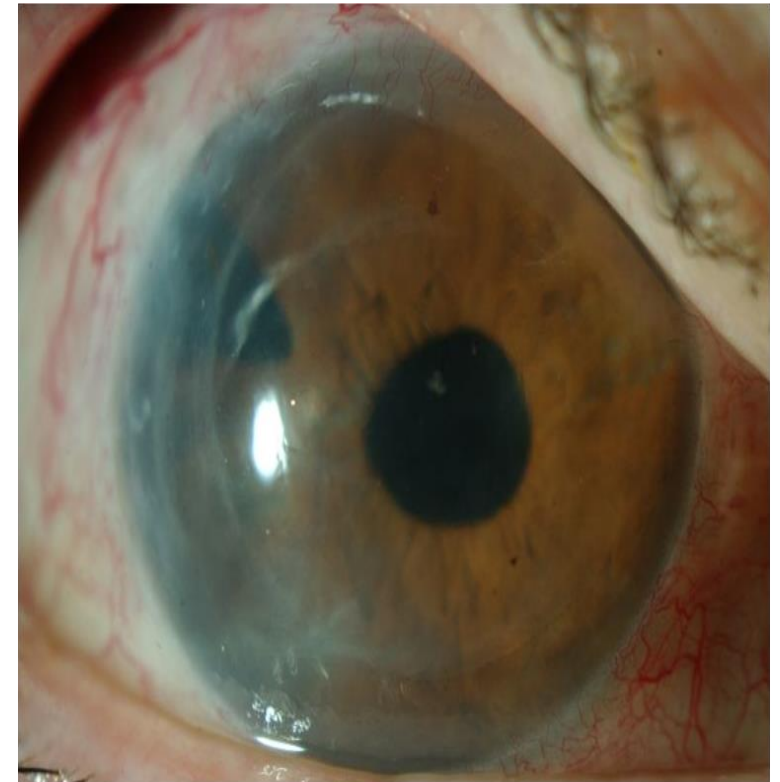- Topical glaucoma medications.
- Less potent steroids.
- Surgical option may be needed for persistent IOP elevation.

Huang OS, Mehta JS, Htoon HM, Tan DT, Wong TT. Incidence and Risk Factors of Elevated Intraocular Pressure Following Deep Anterior Lamellar Keratoplasty. Am J Ophthalmol. 2016; 170:153–60.

Glaucoma after DALK

- 70 years old female that required trabeculectomy first (failed) and then Express P200 valve implant (successful after 3 years fu) to treat persistent elevated IOP after DALK.

DALK



Endothelial keratoplasty after glaucoma surgery

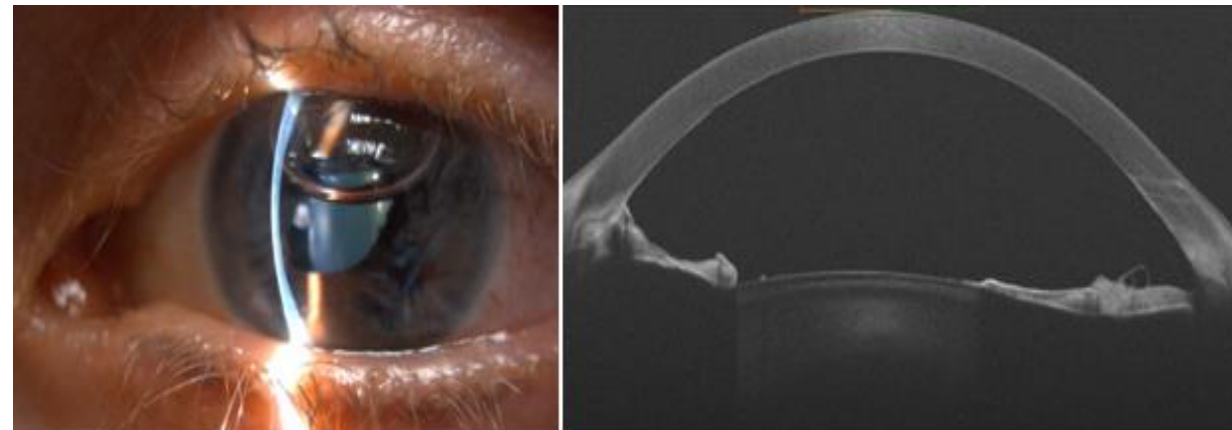
EK can be more challenging in eyes with previous glaucoma surgery as:

- The anterior segment is usually abnormal either due to
 - . Synechiae
 - . The presence of glaucoma tube
- Previous glaucoma surgery increases the risk of graft failure
- The graft failure rates reported for DSAEK with GFD ranging from 18% to 75%.

DMEK AFTER GLAUCOMA SURGERY

- We report a case of a 44 years old female that developed glaucoma after the implantation of artificial iris that eventually required the explantation of the artificial iris and EXPRESS valve (P200) for persistent elevated IOP.
- Due to a decrease in endothelial cell's count and corneal edema, we performed a DMEK with resolution of the edema and clear cornea at the subsequent follow-up visits.
- Both procedures were successful after 3years fu

CASE REPORT (FN: 762559)



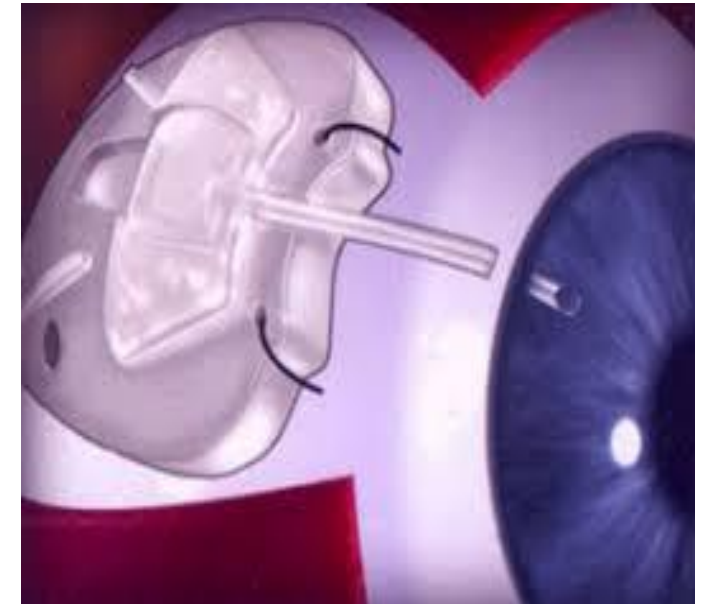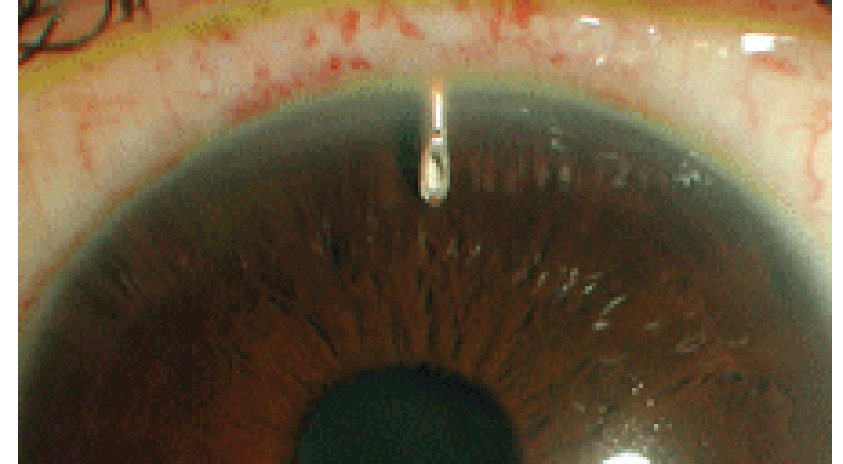
- Some additional procedures and precautions may be needed with DMEK
 - Lysis of the iridocorneal adhesions.
 - Trimming of the tube shunt.
 - Corneal incision should be more corneal rather than limbal to preserve preexisting filtering bleb or GDD.
 - Complete filling of The AC with air at the end of the surgery is recommended.
 - **Repeated filling of the anterior chamber with air or gas for graft attachment is mostly needed.**

2-Glaucoma surgery techniques ... IN CORNEAL GRAFTED EYES

- Glaucoma is a serious and feared condition in corneal transplant cases.
- Adequate control of IOP is mandatory for the survival of both corneal graft and optic nerve.
- Glaucoma surgery becomes necessary if adequate IOP control cannot be achieved by medical treatment alone.

○ Glaucoma procedures include

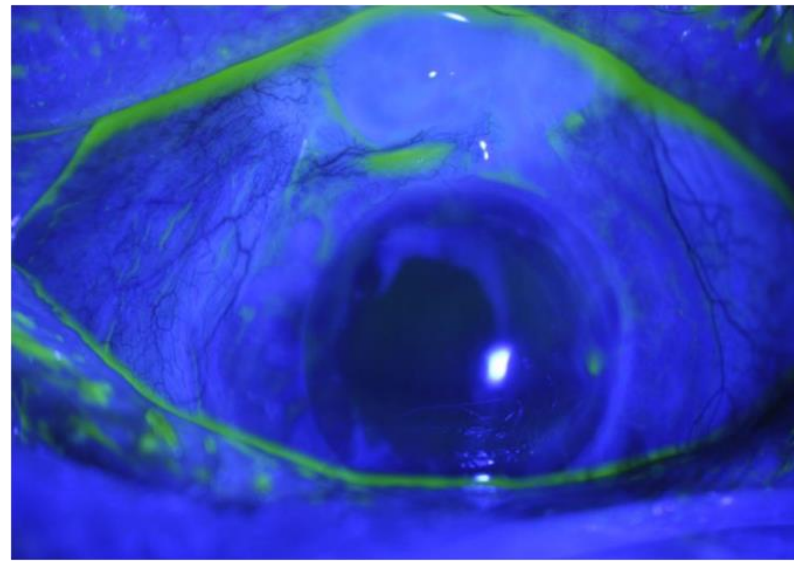
- Trabeculectomy.
- Glaucoma drainage devices (GDD).
- Ex-PRESS mini-glaucoma shunt.
- Deep sclerectomy.
- Cyclophotocoagulation.



1- Trabeculectomy

- The gold standard procedure in the management for glaucoma.
- One of the most widely used surgical procedure in management of glaucoma in corneal transplant cases.
- **Precautions when doing keratoplasty after trabeculectomy:**
- Pay attention especially in PKP to the the conjunctival bleb during trephination.
- Wash the anterior chamber from OVD and any blood remnants from surgical trauma to avoid closure of sclera ostium.

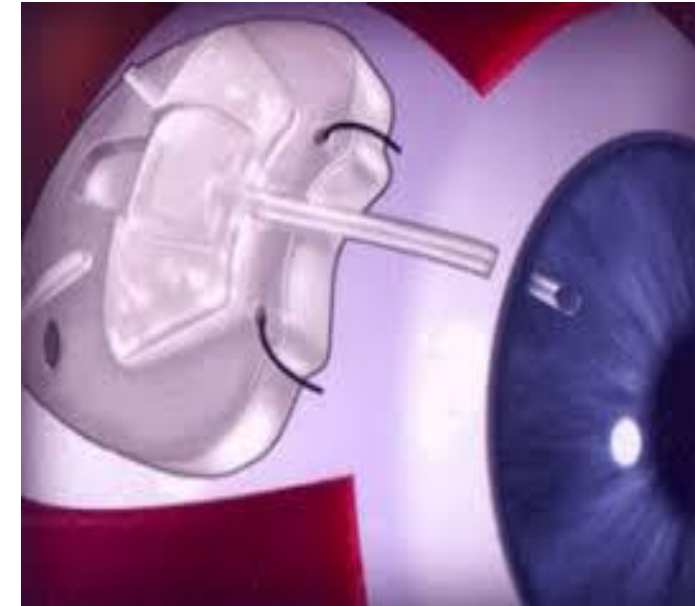
- **Trabeculectomy** was reported to achieve IOP control in glaucoma following lamellar keratoplasty like DALK and DSAEK.
- A recent study reported failure rate about 37% for trabeculectomy following PKP.
- Trabeculectomy alone is less effective in glaucoma following PKP, due to increased risk of bleb failure from persistent conjunctival inflammation and scarring.



FN:767249

2- Glaucoma drainage device (GDD)

- GDD may be valved like Ahmed glaucoma valve or nonvalved like Molteno and Baerveldt implants.
- GDD has a higher success rate in controlling IOP in corneal transplant cases.
- **BUT**, associated with higher endothelial cell loss which affects the graft survival.
- The tube could be implanted in the vitreous cavity especially in eyes with narrow anterior chamber or anatomically disorganized anterior segment.



- The success rate of GDD about 80 % for management of intractable glaucoma after PKP.
- GDD implantation appears to have better outcomes regarding IOP control following PKP when compared to trabeculectomy.
- GDD may be used with DMEK but tube placement in the posterior chamber or vitreous cavity may provide better protection to the graft.

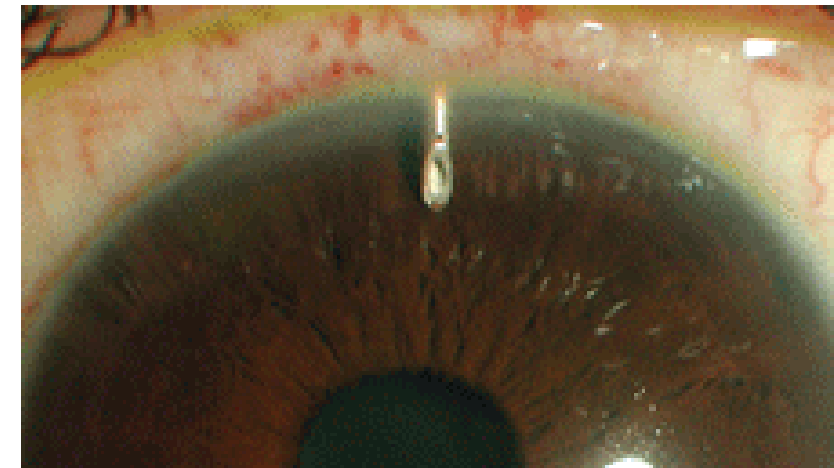

Ayyala RS, Pieroth L, Vinals AF, et al. Comparison of mitomycin C trabeculectomy, glaucoma drainage device implantation, and laser neodymium:YAG cyclophotocoagulation in the management of intractable glaucoma after penetrating keratoplasty. Ophthalmology. 1998;105(8):1550-1556. doi: 10.1016/S0161-6420(98)98046-0.

Almoussa R, Nanavaty MA, Daya SM, Lake DB. Intraocular pressure control and corneal graft survival after implantation of Ahmed valve device in high-risk penetrating keratoplasty. Cornea. 2013;32(8):1099-1104. doi: 10.1097/ICO.0b013e31828d2a17.

Banitt MR, Chopra V. Descemet's stripping with automated endothelial keratoplasty and glaucoma. Current opinion in ophthalmology. 2010;21(2):144-149. doi: 10.1016/S0161-6420(98)98046-0.

3- Ex-PRESS mini shunt

- The Ex-PRESS implant is a small unvalved stainless steel device and is placed as prescribed in literature under the sclera flap of trabeculectomy into the anterior chamber.
- A recent study reported its efficacy and safety with different types of keratoplasty procedures; PKP, DALK and EK.



Ledesma-Gil J, García-Rodríguez ML, Gurria LU, Graue-Hernández EO, Navas A. *Glaucoma*

Mini-Shunt Implantation After Keratoplasty. J Glaucoma. 2017 Apr; 26(4):315-319.

4- Non penetrating deep sclerectomy (NBDS)

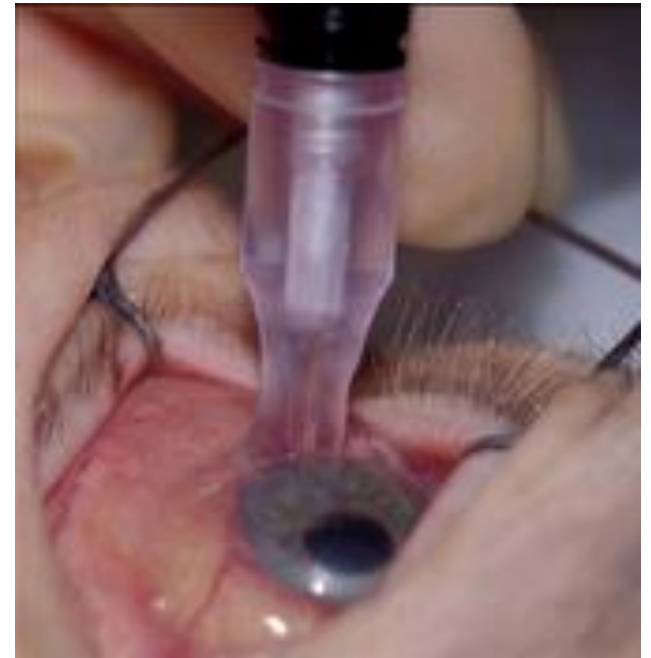- A good option for glaucoma after PKP especially in absence of peripheral anterior synechiae.
- It was reported that the success rates for glaucoma following PKP was 76% and 44% at 1 and 5 years.
- Long term graft survival is better after NBDS than trabeculectomy for glaucoma following PKP.
- Also safer in DMEK cases.

Loriaut P, Nordmann JP, Laroche L, Borderie VM. *Deep sclerectomy versus trabeculectomy in eyes with penetrating keratoplasty.*

Cornea. 2015 Apr; 34(4):375-80.

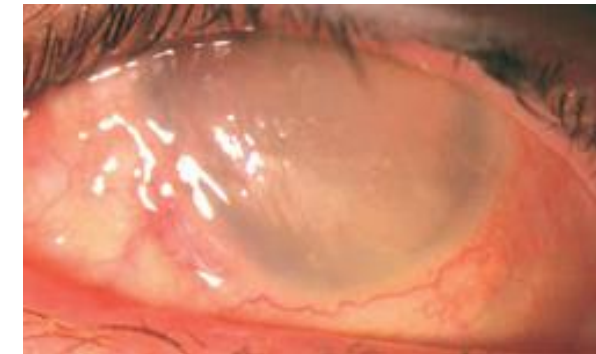
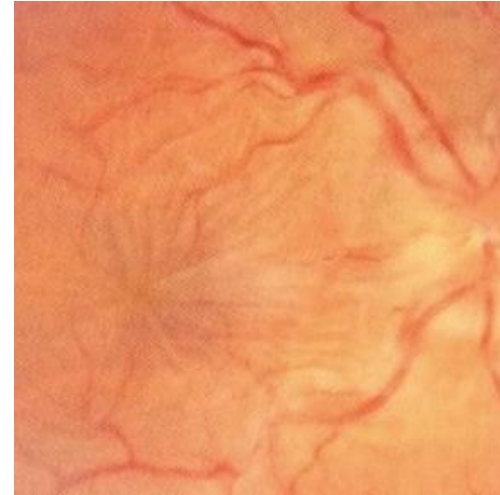
5- Cyclodestructive procedures

- Control the IOP by decreasing aqueous humor production destroying part of the ciliary body.
- These procedures include:
 - . Cyclocryotherapy.
 - . ND:YAG laser cyclophotocoagulation.
 - . Diode laser cyclophotocoagulation.
 - . Transpupillary argon laser photocoagulation.
- Good IOP control results ??



Destructive procedures may be associated to severe complications :

- Hypotony.
- Persistent inflammation.
- Macular edema.
- Corneal decompensation.
- Choroidal and retinal detachment.
- Sympathetic ophthalmitis.
- Phthisis pulbi.



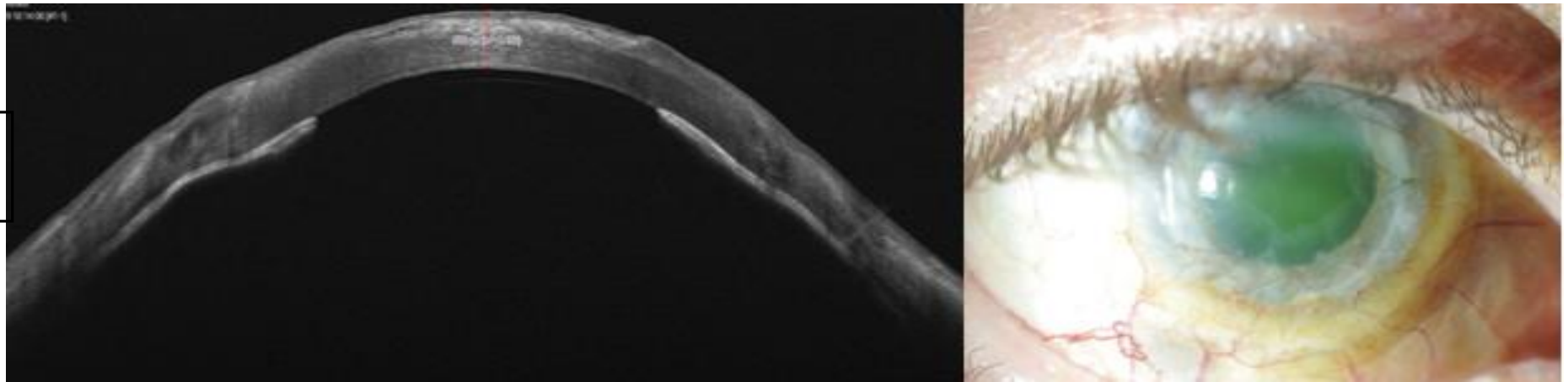
- **Diode laser treatment is associated with lower incidence Of complications and this is probably related to the highly selective destruction of the ciliary body epithelium.**

CYCLOPHOTOCOAGULATION

56 years old diabetic male that developed a refractory glaucoma.

- His ocular anamnesis was positive for a PKP complicated by extensive peripheral anterior synachiae and collapse of the irido-corneal angle.
- Despite being treated with topical glaucoma therapy and implantation of Express Valve, we eventually performed a Cyclophotocoagulation with diode laser to reduce the high values IOP... Visual loss was observed following the procedure

CASE REPORT
(FN:14914)



- A study reported the outcomes of cyclophotocoagulation for glaucoma following PKP; the failure rate was 20.7% .
- A recent study evaluated the use of micropulse transscleral cyclophotocoagulation in 61 keratoplasty eyes with glaucoma; only 10% of cases needed subsequent filtration surgery and graft survival was 94% at 1 year and 81% at 2 years after the initial laser treatment.

Tandon, A., Espandar, L., Cupp, D., Ho, S., Johnson, V., Ayyala, R.S. Surgical management for postkeratoplasty glaucoma: a meta-analysis. J. Glaucoma 2014; 23, 424–429.

Subramaniam K, Price MO, Feng MT, Price FW Jr. Micropulse Transscleral Cyclophotocoagulation in Keratoplasty Eyes. Cornea. 2019 May; 38(5):542-545.



**Take
home message*

- Three important factors are important to be considered for any case of keratoplasty with glaucoma surgery:

IOP control... Graft survival Visual acuity....

- Identifying the risk factors allows attentive follow up and early management.
- Knowledge about adequate management of glaucoma either developed before or after keratoplasty may save a lot of eyes from irreversible damage to the optic nerve and also increases graft survival.

Surgery videos:

<https://goo.gl/PNdZCT>



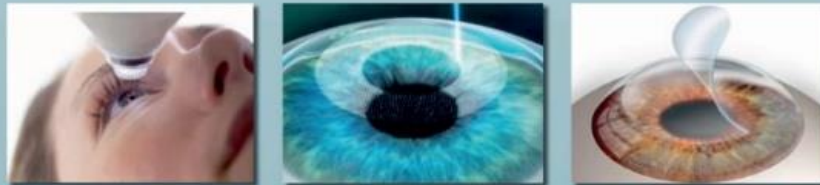
The New International Online Refractive Course
University Certified Specialization Course

Clinical Methodology in Refractive, Cataract and Corneal Surgery Continuous Edition

Course Director:

Jorge L. Alió, MD, PhD, FEBO.

Chairman and Professor of Ophthalmology Universidad de Miguel Hernández, Elche
Alicante, Spain



www.refrativesurgeryonlinecourse.com

Registration and more information: jl.alio@umh.es
Subscribe to: www.facebook.com/umhrefractivecourse

Thank you!!



Jorge L. Alió MD. PhD

Chairman & Medical Director

jlalio@vissum.com

THANK YOU



email

jlalio@vissum.com

