



Prof. Israel Hershkovitz, Ph.D.

Department of Anatomy and Anthropology
Sackler Faculty of Medicine



Evolutionary Medicine, Paleopathology and Bio-history

Position

Professor, Sackler Faculty of Medicine

Head, Dan David Laboratory for the Search and Study of Modern Humans

Director, Tassia and Joseph Meychan Chair for the History and Philosophy of Medicine

Research

Biohistory: The social and biological impact the transition from foraging and hunting to farming had on human populations. Although a rapid event in human evolution, the 'agriculture revolution' was the most significant cultural process in human history, something that forever changed the face of humanity (culturally and biologically). Unlike many other paleoanthropological studies, we adopt an 'osteobiographic' approach, i.e., life history as recorded in bones. The study is based on several hundreds of Natufian and Neolithic skeletons (large portion of them were excavated by the team), housed at Tel Aviv University. The study, besides traditional methods, applies new methods and technologies as CT, Micro-CT, SEM, Histochemistry, aDNA, Isotope analyses.

Human evolution: Searching for the origin of anatomically modern humans. The origin of anatomically modern *Homo sapiens* and the fate of

the Neanderthals have been fundamental questions in human evolutionary studies for over a century. New fossils excavated at Qesem, Misliya and Manot caves, may shed light on the above questions.

Evolutionary medicine: This section is divided into three topics: 1) Establishing valid methods for identifying diseases in ancient bones, 2) Identifying diseases in the fossil record, 3) Evolutionary perspective of current diseases.

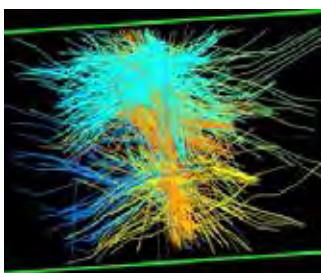
Publications

Masharawi Y, Dar G, Peleg S, Steinberg N, Medlej B, May H, Abbas J, **Hershkovitz I**. A morphological adaptation of the thoracic and lumbar vertebrae to lumbar hyperlordosis in young and adult females. *Eur Spine J*. 2010, 19: 768-773.

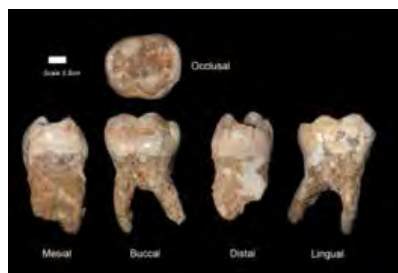Dar G, Masharawi Y, Peleg S, Steinberg N, May H, Medlej B, Peled N, **Hershkovitz I**. Schmorl's nodes distribution in the human spine and its possible etiology. *Eur Spine J*. 2010, 19: 670-675.

Hay O, **Hershkovitz I**, Rivlin E. Spine curve modeling for quantitative analysis of spinal curvature. *Conf Proc IEEE Eng Med Biol Soc*. 2009;1:6356-9.

Wasser DE, **Hershkovitz I**. The question of ethnic variability and the Darwinian significance



3D reconstruction of the annulus fibrosus, MRI study. Disc herniation project.



Teeth from Qesem cave 300,000 years. Modern human origin project.



Hyperostosis frontalis interna (HFI) identified via CT and direct observation (skeletal).

of physiological neonatal jaundice in East Asian populations. *Med Hypotheses*. 75: 187-189.

Galili E, Eshed V, Rosen B, Kislev ME, Simchoni O, **Hershkovitz I**, Gopher A. Evidence for a separate burial ground at the submerged pottery Neolithic site of Neve-Yam, Israel. *Paleorient* 2010, 35: 31-46.

Abbas J, Hamoud K, Masharawi YM, May H, Medlej B, Peled N, **Hershkovitz I**. Ligamentum flavum thickness in normal and stenotic lumbar spine. *Spine* 2010, 20:35:1225-1230.

May H, Peled N, Dar G, Abbas J, Medlej B, Masharawi Y, Hershkovitz I. Hyperostosis frontalis interna and androgen suppression. *Anat Rec (Hoboken)*. 2010, 293:1333-6.

Abbas J, Hamoud K, May H, Hay O, Medlej B, Masharawi Y, Peled N, **Hershkovitz I**. Degenerative lumbar spinal stenosis and lumbar spine configuration. *Eur Spine J*. 2010, 19:1865-1873.

Eshed V, Gopher A, Pinhasi R, **Hershkovitz I**. Paleopathology and the origin of agriculture in the Levant. *Am J Phys Anthropol*. 2010 Set 143:121-133.

May H, Peled N, Dar G, Cohen H, Abbas J, Medlej B, **Hershkovitz I**. Hyperostosis frontalis interna: criteria for sexing and aging a skeleton. *Int J Legal Med*. 2011, 125:669-73.

137. N. Steinberg, I. Siev-Ner, S. Peleg, G. Dar, Y. Masharawi, A. Zeev and **I. Hershkovitz**. Injury patterns in young, non-professional dancers. *J Sports Sci* 2011, 29:47-54.

May H, Peled N, Dar G, Hay O, Abbas J, Masharawi Y, **Hershkovitz I**. Identifying and classifying hyperostosis frontalis interna via computerized tomography. *Anat Rec (Hoboken)*. 2010; 293:2007-2011.

Dar G, Masharawi Y, Peleg S, Steinberg N, May H, Medlej B, Peled N, **Hershkovitz I**. The epiphyseal ring: a long forgotten anatomical structure with significant physiological function. *Spine (Phila Pa 1976)*. 2011, 36:850-6

Hershkovitz I, Smith P, Sarig R, Quam R, Rodríguez L, García R, Arsuaga JL, Barkai R, Gopher A. Middle pleistocene dental remains from Qesem Cave (Israel). *Am J Phys Anthropol*. 2011, 144: 575-592.

May H, Peled N, Dar G, Abbas J, **Hershkovitz I**. Hyperostosis frontalis interna: What does it tell us about our health? *Am J Hum Biol*. 2011, 23:392-7.

Abbas J, Hamoud K, Peleg S, May H, Masharawi Y, Cohen H, Peled N, **Hershkovitz I**. Facet joints arthrosis in normal and stenotic lumbar spines. *Spine (Phila Pa 1976)*. 2011, 36:E1541-6.

Hamoud K, **Hershkovitz I**, Hanani A, Marom L, Abbas J. Internal stabilization of a flexion-distraction injury of the upper cervical spine of a toddler. A new technique and literature review. *Spine (Phila Pa 1976)*. 2011, 37:E400-7.

V. Sloan, Nagar Y, Kuperman T, **Hershkovitz I**. A case of a Dwarfism from the Byzantine city Rehovot-in-the-Negev, Israel. *Int J Osteoarchaeology* 2011, DOI:10.1002/oa.1285.

M. Ben-Dor, Gopher A, **Hershkovitz I**, Barkai R. Man the fat hunter: the demise of Homo erectus and the emergence of a new hominin lineage in the Middle Pleistocene (ca. 400 kyr) Levant. *PLoS One*. 2011;6:e28689.

N. Steinberg, **Hershkovitz I**, Peleg S, Dar G, Masharawi Y, Siev-Ner I. Paratenonitis of the foot and ankle in young female dancers. *Foot Ankle Int*. 2011, 32:1115-21.

N. Steinberg, Siev-Ner I, Peleg S, Dar G, Masharawi Y, Zeev A, **Hershkovitz I**. Extrinsic and intrinsic risk factors associated with injuries in young dancers aged 8-16 years. *J Sports Sci*. 2012, 30:485-95.

N. Steinberg, Siev-Ner I, Peleg S, Dar G, Masharawi Y, Zeev A, **Hershkovitz I**. Joint range of motion and patellofemoral pain in dancers. *Int J Sports Med*. 2012, 33:561-6.

V. Slon, **Hershkovitz I**, Peled N. Dyke-Davidoff-Masson syndrome in a 6,000-year-old skull. *Neuroradiol*. 2012, 54:1413-5.

H. May, Mali Y, Dar G, Abbas J, **Hershkovitz I**, Peled N. Intracranial volume, cranial thickness, and hyperostosis frontalis interna in the elderly. *Am J Hum Biol* 2012, 24:812-819.

H. Cohen, Sarie I, Medlej B, Bocquentin F, Toledano T, **Hershkovitz I**. and Slon, V. Trauma to the skull: A historical perspective from the Southern Levant (4300BCE–1917CE). *Int J Osteoarchaeol*. 2012, DOI: 10.1002/oa.2258

H. Cohen, Slon V, Barash A, May H, Medlej B. and **Hershkovitz I**. Assyrian attitude towards captive enemies: A 2700 years old paleo-forensic study. *Int J Osteoarchaeol*. 2012, DOI: 10.1002/oa.2288

R. Sarig, Lianopoulos NV, **Hershkovitz I**, Vardimon AD. The arrangement of the interproximal interfaces in the human permanent dentition. *Clin Oral Investig*. 2013, 17:731-8

N. Steinberg, **Hershkovitz I**, Peleg S, Dar G, Masharawi Y, Zeev A, Siev-Ner I. Morphological characteristics of the young scoliotic dancer. *Phys Ther Sport*. 2013, 14:213-20.

V. Slon, **Hershkovitz I**, May H. The value of cadaver CT scans in gross anatomy laboratory. *Anat Sci Educ*. 2014, 7:80-2.

N. Steinberg, Siev-Ner I, Peleg S, Dar G, Masharawi Y, Zeev A, **Hershkovitz I**. Injuries in female dancers aged 8 to 16 years. *J Athletic Training*, 2013, 48:118-123.

H. Cohen, V. Sloan, H. May, **I. Hershkovitz**, E. Peled, D. Norman. Musculoskeletal wounds characteristic of the second Lebanon war. *Forensic Med Anat Res*. 2013, 1:14-17.

H. May, Cohen H, Medlej B, Kornreich L, Peled N, **Hershkovitz I**. Computed tomography-enhanced anatomy course using enterprise visualization. *Anat Sci Educ*. 2013, 6:332-41.

H. Valladas, Mercier N, **Hershkovitz I**, Zaidner Y, Tsatskin A, Yeshurun R, Vialettes L, Joron J-L, Reyss J-L, Weinstein-Evron M. Dating the Lower to Middle Paleolithic transition in the Levant: A view from Misliya Cave, Mount Carmel, Israel. *J Hum Evol*. 2013, X: 1-9.

J. Abbas, Hamoud K, May H, Peled N, Sarig R, Stein D, Alperovitch-Najenson D, **Hershkovitz I**. Socioeconomic and physical characteristics of degenerative lumbar spinal stenosis individuals. *Spine (Phila Pa 1976)*. 2013 Feb 1. [Epub ahead of print]

R. Sarig, Slon V, Abbas J, May H, Shpack N, Vardimon AD, **Hershkovitz I**. Malocclusion in early anatomically modern human: a reflection on the etiology of modern dental misalignment. *PLoS One*. 2013;8:e80771

Slon V, Sarig R, **Hershkovitz I**, Khalaily H, Milevski I. The plastered skulls from the Pre-Pottery Neolithic B site of Yiftahel (Israel)--a computed tomography-based analysis. *PLoS One*. 2014 9:e89242

Reviews

V. Slon, **Hershkovitz I**, Peled N. Dyke-Davidoff-Masson syndrome and fibrous dysplasia: response to a "Letter to the Editor". *Neuroradiology*. 2012, 54: 1029-1030.